



**PATIENT**

Olive Lehman

**SPECIES**

Canine

**BREED**

Sheltie

**SEX**

Female Spayed

**AGE**

1.20.14

**WEIGHT**

19.5lbs

**PRESENTING CLINICAL SIGNS**

History: Recheck echo; ho DCM. New grade I-II heart murmur heard 10/22.

-Pertinent abnormal PE/Chem/CBC/UA Results: 10/22- Chem 10- ALKP 813, ALT 144

-Current medications: Pimobendan 2.5mg BID, Furosemide 10mg BID, Spironolactone 25mg 1/2 BID, Clindamycin 75mg BID.

-Sedation used: Not required to complete full diagnostic ultrasound.

-Pertinent previous ultrasound results (6/2022 MML): LVE with FS: 19%. LV: 3.7/3.1. Severe LAE: 2.9cm. Mild to moderate MR, mild RHE.

-STAT: Not requested.

-Imaging performed by: Stephanie Warga RDCS, RVT.

**ECHOCARDIOGRAM FINDINGS**

2D, m-mode, color flow and doppler imaging is available. Significant left ventricular dilation with borderline systolic function and increased sphericity. Decreased LV wall thickness. Severe left atrial enlargement. The mitral valve appears mildly thickened, with no obvious prolapse into the left atrial lumen. Mild to moderate eccentric mitral regurgitation. Elevated velocity. Tricuspid valve appears normal in form and function. Mild right atrial and ventricular dilation. No significant tricuspid regurgitation. The aortic valve is normal in morphology and mobility. Normal LVOT and RVOT velocities. No aortic or pulmonic insufficiency. No pericardial or pleural effusion noted. No obvious cardiac tumors.

**CARDIAC CHART**

**INTERPRETED BY**

Maggie Machen Lamy, DVM, DACVIM (Cardiology)

**HOSPITAL NAME**

Hickory Veterinary Hospital

**REFERRING VET**

Dr. Lyle

**INVOICE**

27336

**DATE**

11.8.22

CANINE CARDIAC PARAMETERS	MR VMAX (m/s)	TR VMAX (m/s)	LA/AO (Boon method)	LA/AO (Heart Base; Swe)	FS (%)	EF (%)	EPSS (cm)
NORMAL PARAMETER	4.5-5.5	<2.7	1.3	<1.6	28-40	40-100	<0.6
PATIENT	6.4	NA	NM	2.0	28	56	NM
CANINE CARDIAC PARAMETERS	HR (BPM)	AV VMAX (m/s)	PV MAX (m/s)	BODY WEIGHT (kg)	LA 2D short axis Base view (cm)	LVIDd Avg; 2D and m-mode short axis (cm)	LVIDs Avg; 2D and m-mode short axis (cm)
NORMAL PARAMETER	50-100	0.7-1.7	0.7-1.6	BELOW	BELOW	BELOW	BELOW
PATIENT	150	1.8	1.2	8.8	2.4	3.6	2.6
*Normal chamber parameters expressed as a mean value (SD)				3	1.27 (5.3)	2.46 (2.46)	1.36 (5.5)
<b>BODY WEIGHT DEPENDENT PARAMETERS</b>				5	1.40 (4.5)	2.74 (5.2)	1.60 (4.7)
<i>*Note: All measurements based upon multi-modal images and methods. An average value is reported.</i>				10	1.50 (3.8)	3.27 (3.5)	2.06 (3.1)
				15	1.83 (2.0)	3.71 (2.4)	2.43 (2.1)
				20	2.02 (1.9)	4.14 (2.2)	2.80 (2.0)
				25	2.18 (2.4)	4.48 (2.9)	3.10 (2.5)
				30	2.33 (3.3)	4.83 (3.9)	3.39 (3.4)
				35	2.48 (4.3)	5.17 (5.0)	3.69 (4.5)
				40	2.62 (5.2)	5.48 (6.1)	3.96 (5.4)
				50	2.88 (7.1)	6.07 (8.3)	4.46 (7.4)

Adapted from June Boon, Veterinary Echocardiography, 1998  
 Rishniw M and Hollis NE, J Vet Intern Med 2000; 14:429-435  
 Hansson et al, Vet Rad and Ultrasound 2002  
 Bonagura et al. Echocardiography: principles of interpretation, Vet Clin North Am 15:1177, 1995

### INTERPRETATION OF THE FINDINGS & FURTHER RECOMMENDATIONS

Compared to the prior study, the left and right heart dimensions appear similar. What is unexpected is the systolic is improved comparatively, which is difficult to explain. Regardless, this reflects stable disease with no progression seen.

Given these findings, continue cardiac support going forward. Occasional premature beats are noted throughout the study and a screening ECG and BP are recommended.

Elective anesthesia is not advised due to high risk for complications.

Omega fatty acid supplementation and mild salt restriction may be of some long-term benefit. Monitor for development of a cough, worsening labored breathing, abdominal distention, exercise intolerance or collapse episodes in the future. Monitoring of sleeping breathing rates at home is recommended to assess response to medications and recurrence of CHF in the future.

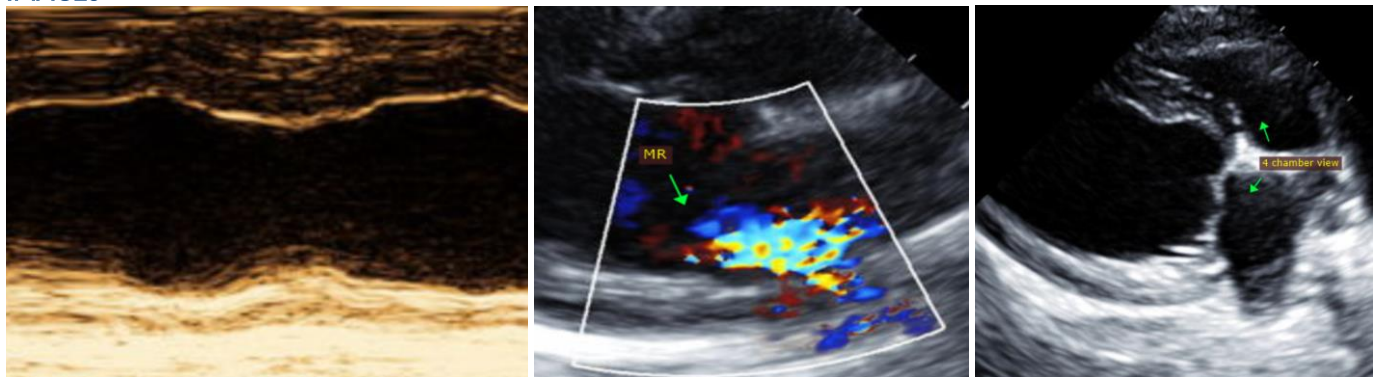
### PLAN:

Continue Pimobendan, Spironolactone and Lasix as prescribed. A screening ECG is recommended.

Monitor a renal panel and blood pressure every 3-4 months lifelong.

A recheck echocardiogram is recommended in 6 months to screen for progression, sooner if clinical issues arise in the interim.

### IMAGES



**The information and recommendations provided are based on the images presented by the referring veterinarian. No evaluation can be communicated regarding pathology that was not visible in the image/video clips provided.**

Thank you for this referral. This report was generated using transcription software, and minor dictation errors may be present. If the clinical or image interpretation does not parallel your findings or if I can be of any further assistance, please contact me.

**Maggie Machen Lamy, DVM**  
**Diplomate of the American College of Veterinary Internal Medicine (Cardiology)**  
**info@sonopath.com**